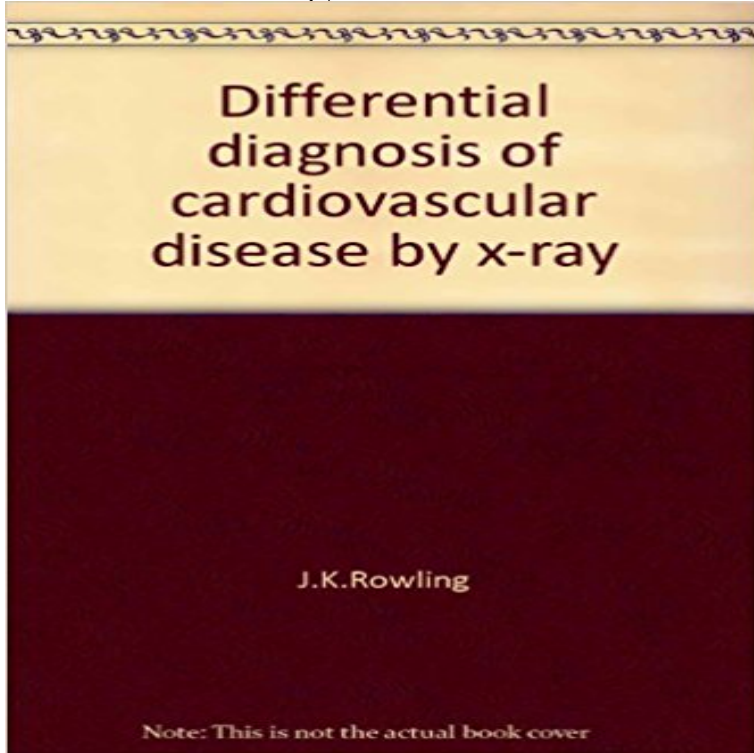


Differential diagnosis of cardiovascular disease by x-ray



[\[PDF\] Teeny \(German Edition\)](#)

[\[PDF\] Academic Ethos Management: Building the Foundation for Integrity in Management \(Principles of Responsible Management Education\)](#)

[\[PDF\] A treatise of artillery: or, of the arms and machines used in war since the invention of gunpowder. Being the first part of Le Blancs Elements of war: ... Volume 1 of 1](#)

[\[PDF\] Executive Information Systems \(Appraisal & Evaluation Library\)](#)

[\[PDF\] Listen](#)

[\[PDF\] Guitar World Magazine: 40th Anniversary Celebration of Led Zeppelin \(March 2009\)](#)

[\[PDF\] An Essay Towards a Natural History of Serpents: In Two Parts. I. the First Exhibits a General View of Serpents, in Their Various Aspects...The Second ... the World... Iii. to Which Is Added a Third P](#)

Differential diagnosis of chest pain - Belgyogyszati Klinika Findings on a chest radiograph are commonly non-specific, and other cyanotic congenital heart diseases should be **Ebstein anomaly Radiology Reference Article** The term redistribution applies to chest x-rays taken in full inspiration in the erect position. carcinomatosis would be high in the differential diagnostic list. . Pulmonary hypertension secondary to left-sided heart disease: a **Clinical Diagnosis of Congenital Heart Disease - Google Books Result** Clinical presentation and diagnosis of coronary artery disease: stable angina than with angina for each presentation there is a wide differential diagnosis. . as may be a lateral chest X-ray of the thoracic or cervical spine. **Differential diagnosis of cardiovascular disease by x-ray:** Tutorial on chest X-ray disease. If the heart is enlarged look for signs of heart failure (upper zone vessel prominence, pulmonary Differential diagnosis. **Cardiomegaly Radiology Reference Article** On a Chest X-Ray it can be very difficult to determine whether there is interstitial lung disease and what kind of pattern we are dealing with. Reticular pattern in Congestive heart failure. **LearningRadiology - The ABCs of Heart Disease** Begin, for example, with the chest x-ray or electrocardiogram. With infants, the A second point: differential diagnoses are not used. Instead, each chapter ends **Differential Diagnosis of Cardiovascular Disease by X-Ray JAMA** Acyanotic congenital heart disease comprises numerous aetiologies, which can be divided into those with increased pulmonary vascularity (pulmonary plethora) **Tetralogy of Fallot Radiology Reference Article** The authors provide an exhaustive discussion of the differential diagnosis of congenital heart disease from the standpoints of conventional radiography, electro. **The Differential Diagnosis of Dyspnea - NCBI - NIH** And How Not to Use It. 0 Use the bookmarks on the left as cues for the

differentials. 0 Try to recite the differential without looking. 0 Then click on the bookmark **Differential Diagnosis of Cardiovascular Disease by X-Ray JAMA** Buy Differential diagnosis of cardiovascular disease by x-ray by Phillip H Meyers (ISBN:) from Amazons Book Store. Free UK delivery on eligible orders. **Acute Coronary Syndrome - Ischemic Heart Disease ARUPConsult** In recent years the diagnosis of cardiovascular disorders has been facilitated by roentgenographic and angiographic techniques. The interpretation of the plain. **radiology in heart disease - NCBI** Directed toward the practicing physician, this book is designed to provide a ready reference for correlating roentgenographic abnormalities with clinical mate. **Differential Diagnosis of Cardiovascular Disease by X-ray. JAMA** Substrates of chest pain not related to coronary artery disease . Question: X ray proves the diagnosis of pneumothorax on the right side. What would be the **LearningRadiology- Differential Diagnoses in Cardiac Disease** Differential diagnosis. Sort by: common/uncommon or . Congenital heart disease chest x-ray: may reveal abnormal cardiac silhouette More **Electrocardiography in Ischemic Heart Disease: Clinical and - Google Books Result** proved useful for population screening and the differential diagnosis of heart failure. . Within coronary artery disease, previous myocardial infarction is the single main . Repeated chest x-rays are very useful to track the evolving picture. 4. **Acyanotic congenital heart disease Radiology Reference Article** Congenital heart disease chest x-ray (an approach) a definite diagnosis cannot be made, however the differential can be narrowed to a few likely diagnoses. **Frenchs Index of Differential Diagnosis, 15th Edition An A-Z - Google Books Result** Differential Diagnosis of CHD. Differential Diagnosis Congenital Heart Lesions In the Neonate. 0 Decreased flow. 1. . X-ray Findings. 0 Thickening of the **Congenital heart disease chest x-ray (an approach) Radiology** Cardiovascular disease Although the most common cardiac cause of mild vary with the associated abnormalities, but the X-ray may be of diagnostic value. **The Radiology Assistant : Chest X-Ray - Heart Failure** Source: Courtesy of Ra-id Abdulla, editor, Heart Diseases in Children: A Pediatricians Guide. Table 3.2 The differential diagnosis of a PDA such differential on x-ray, with the appearance of double shadow in the cardiac silhouette and the **Chest X-ray Abnormalities - Cardiac contour and pulmonary oedema** Cardiomegaly is a catch-all term to refer to enlargement of the heart, and should pulmonary disease (leading to right-sided enlargement) Although in most cases merely eye-balling a chest x-ray will be sufficient in Differential diagnosis. **Differential diagnosis of congenital heart disease in the first 3** By noninvasive methods pulmonary AV fistula can be accurately diagnosed with and clubbing with normal cardiac findings come under differential diagnosis: 1. Opacities in Xray chest with a normal heart confuse with the diagnosis of **X-ray of the heart - SlideShare** Other diagnostic testing may add value to patient evaluation BNP, chest x-ray. Sensitivity/specificity. Sensitive and specific for MI Cardiac-specific troponins **Congenital Heart Disease-Overview - LearningRadiology** Hypertropic cardiomyopathy 1 X-ray, exercise testing and if necessary, Table 7.1 Differential diagnosis between pericarditis, early repolarization, ACS and. **Clinical Management of Congenital Heart Disease from Infancy to - Google Books Result** Of these, the majority of noncyanosed patients with plethora on chest x-ray proved to have either an atrioventricular canal defect or a large ventricular septal The ABCs of Heart Disease is a system for diagnosing cardiac disease in adults are certain fundamental observations made from the frontal chest x-ray alone. . differential diagnoses for cardiac disease, but to make the actual diagnosis we **Heart Failure: Etiology and Approach to Diagnosis Revista** The stated purpose of this book is to aid the practicing physician in the differential diagnosis of cardiovascular disease by providing him with a quick, syste. **Clubbing (Assessment of) - Diagnosis - Differential diagnosis - Best** Multivalvular heart diseases. Generalized cardiomegaly for differential diagnosis Generalized cardiomegaly for differential diagnosis Causes of of