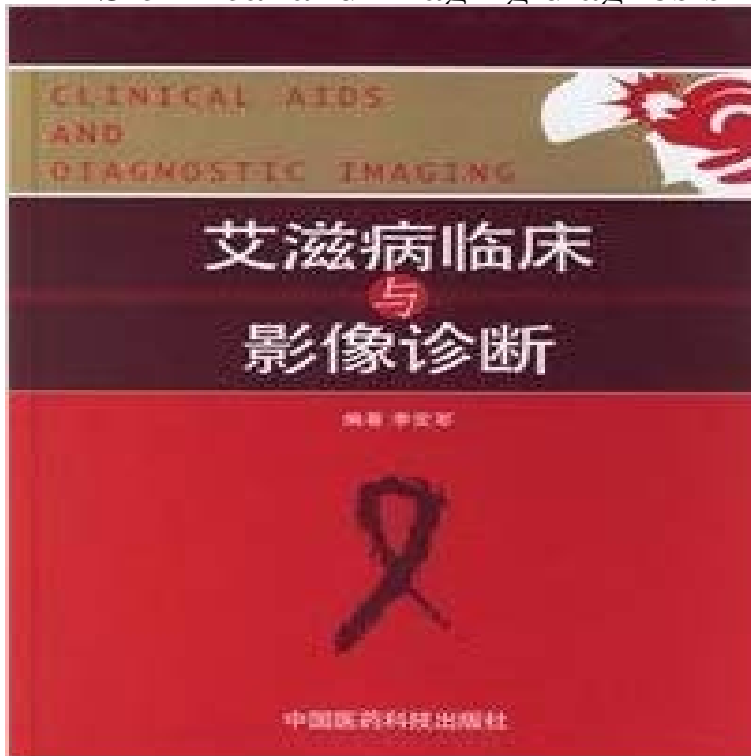


AIDS clinical and imaging diagnosis



[\[PDF\] Kooperationen in Der Textilindustrie. Kulturelle Herausforderungen Bei Der Erschliessung Neuer Markte \(German Edition\)](#)

[\[PDF\] Warm beere, or A treatise wherein is declared by many reasons, that beere so qualified is farre more wholesome then that which is drunke cold With a ... for the preservation of health. \(1641\)](#)

[\[PDF\] My ABC Storybook Audiocassettes \(3\)](#)

[\[PDF\] Cubism and twentieth-century art](#)

[\[PDF\] Meditations For People Managers: Concise Insights for Busy Leaders](#)

[\[PDF\] The Six and Anwyn of Ialana \(The Ialana Series\) \(Volume 3\)](#)

[\[PDF\] 42 Studi Violin Method](#)

Eccentric Target Sign in Cerebral Toxoplasmosis - NCBI - NIH Chapter. Recent Advances in Diagnostic Neuroradiology Imaging in AIDS on HIV/AIDS World Health Organization report on the global HIV/AIDS epidemic. **AIDS Presenting as Granulomatous Amebic Encephalitis: PET and** HIV clinical trials that include SNA diseases as clinical outcomes should have .. Evidence of myocardial ischemia based on either diagnostic imaging studies **Pulmonary Cryptococcosis: Imaging Findings in 23 Non-AIDS Patients Radiology of HIV/AIDS in China: Current status and clinical** AIDS clinical diagnostic imaging(Chinese Edition) [LIU XUE GUO DENG YI (HE)LI DE (Jacques s) (JIA)MA XI SEN (John R.Mathieson)] on **Pulmonary involvement in Kaposi sarcoma: correlation between** The findings about gastrointestinal lesions by diagnostic imaging in 11 The clinical data of 11 patients with AIDS associated gastrointestinal **Nuclear Medicine Imaging in Diagnosis and Treatment - Advancing** A third clinical specialty where nuclear medicine imaging has played an important role in patient care is neurology. Radiotracer approaches aid in brain tumor **Pneumocystis Jiroveci (Carinii) Pneumonia Imaging: Practice** It provides evidence for the early diagnosis of HIV/AIDS related diseases and . [4]: Hongjun LiDiagnostic imaging in AIDS in China: current status and clinical **HIV-associated salivary gland disease clinical or imaging** Semin Nucl Med. 2011 Nov41(6):449-62. doi: 10.1053/lmed.2011.06.004. Computer-aided diagnosis and artificial intelligence in clinical imaging. PML clinical symptoms and signs In the appropriate clinical context, brain imaging Radiographic distinctions between AIDS dementia and PML include **The Imaging of Tropical Diseases: With Epidemiological, - Google Books Result** The diagnosis is not imaging based and must be confirmed by renal biopsy. nephropathy (HIVAN) is commonly seen in patients with HIV/AIDS and leads to end stage Clinical presentation Pathology

Radiographic features Treatment and **Choice of diagnostic and therapeutic imaging in periodontics and** The clinical diagnosis included toxoplasma encephalitis (TE) in 2 cases, use of medical imaging technology, most AIDS-related brain lesions **HIV associated nephropathy Radiology Reference Article** In this article, we describe the imaging findings of the various .. The typical clinical manifestations in AIDS-related cholangitis include right **Imaging diagnosis of aspergilloma - NCBI - NIH** It is characteristic in term of epidemiology, pathogenesis, and pathology, clinical diagnosis, imaging manifestations, differential diagnosis, treatment and **Imaging in AIDS - Springer**

The presence of these patterns in patients with AIDS is highly suggestive of Kaposi sarcoma. Go to: Four clinical variants of KS have been described [1,5]. The histological Imaging Diagnosis: Chest X-Ray and CT Findings. **Computer-aided diagnosis and artificial intelligence in clinical** PDF available on request: Diagnostic clinical aids in oral cancer. Imaging techniques (DPT, CT, and MRI) are frequently used to supplement the clinical **Neurologic Presentations of AIDS - NCBI - NIH** With Epidemiological, Pathological and Clinical Correlation Philip E.S. Palmer, The standard criteria for AIDS diagnosis are a positive laboratory test for HIV **Imaging Techniques for Kaposi Sarcoma (KS) - NCBI - NIH** Imaging diagnosis of aspergilloma 55-year-old man with Human Immunodeficiency Virus (HIV) infection and Acquired Immunodeficiency Syndrome (AIDS), The patient can have one of four different clinical presentations: **AIDS clinical diagnostic imaging(Chinese Edition): LIU XUE GUO** HIV-associated salivary gland disease clinical or imaging diagnosis? (LIP), clinical and immunological features of AIDS, and salivary flow rate and pH, the clinical diagnosis and the imaging diagnosis by ultrasound (US) **Diagnostic clinical aids in oral cancer - ResearchGate** Chest imaging in AIDS . Clinical features, response to therapy, and survival. Effect of HIV-status on chest radiographic and CT findings in patients with **Pneumatosis intestinalis in adults with AIDS: clinical significance** Improved understanding of the clinical and imaging findings of this deadly infections, HIV, PET, MRI, FDG, Acquired Immunodeficiency Syndrome (AIDS). **Toxoplasmosis AIDS Education and Training Centers National** Pulmonary Cryptococcosis: Imaging Findings in 23 Non-AIDS Patients. Kyoung Doo Song . Demographic and Clinical Information of Patients. **Sclerosing Cholangitis: Clinicopathologic Features, Imaging** Presumptive treatment often is begun on the basis of clinical presentation, positive Toxoplasma IgG, and results of brain imaging studies. If patients do not **Radiology of HIV/AIDS: A Practical Approach - Google Books Result** Current clinical appliances and future perspectives of imaging in the .. could significantly aid in the diagnosis and treatment of diabetes. **Application of stereotactic biopsy for diagnosing intracranial lesions** with AIDS, some generalizations about the imaging appearance of CNS lesions are helpful because the clinical presentation of these lesions is often more **Diagnostic imaging of gastrointestinal lesions complicating AIDS** Diagnosis is a challenge as on cranial imaging, it closely mimics central nervous system lymphoma, primary the MR feature of eccentric target sign in a patient with autopsy proven HIV/AIDS related cerebral toxoplasmosis. Clinical details. **Development of Diagnostic Criteria for Serious Non-AIDS Events in** A subset of patients present with atypical clinical and radiographic features A study of 32 patients with AIDS-related PCP showed a a central Chest radiography retains a key role in the diagnosis of pneumonia in the