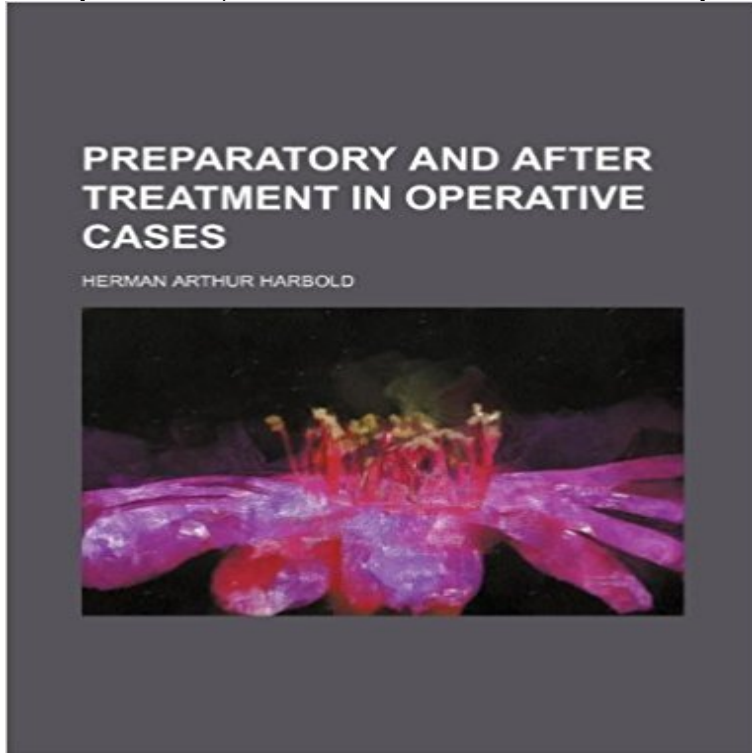


## Preparatory and after treatment in operative cases



This historic book may have numerous typos and missing text. Purchasers can download a free scanned copy of the original book (without typos) from the publisher. Not indexed. Not illustrated. 1910 Excerpt: ...lower portion of the parietal tubercle, and in the occipitopetal type more toward its posterior aspect. In children during the first two years of life the squamous bone is quite small, and the parietal bone reaches to or extends below the first temporal sulcus. In these instances the fissure of Sylvius is covered entirely by the parietal bone. The fissure divides into three branches, ramus anterior horizontalis, ramus anterior ascendens and ramus posterior horizontalis. The latter represents as the main branch the greater part of the fissure. The origin of the two anterior branches corresponds to the punctum Sylvii (Sylvian point of the English), which is located at the pterion. The ramus anterior ascendens lies vertically to the ramus posterior horizontalis; the ramus anterior horizontalis runs from the pterion beneath the sphenoparietal suture with reliable persistence in an anterior direction. 3. The three frontal convolutions lie with their posterior ends in contact with the precentral convolution, i. e.. about 22 mm. from the central fissure. The first begins 1 cm. from the median line, taking the longitudinal sinus into account. The second is located with its middle (in children. Fere) under the center of the frontal eminence, while in the adult this point corresponds to the first frontal fissure or to the border between the inner and outer two-thirds of the second frontal convolutions (Poirier). The third is situated about the rami anterior horizontalis and ascendens of the fissure of Sylvius. 4. The three lateral temporal convolutions occupy the space at the side of the brain between the fissure of Sylvius and the temporal border. The latter in the average

corresponds to a line 5 mm. above the upper edge of the external auditory meatus, that is, i...

**Image from page 433 of Preparatory and after treatment in Flickr** File:Preparatory and after treatment in operative cases (1910) (14760480646).jpg. From Wikimedia Commons, the free media repository. **Preparatory and after treatment in operative cases : Herman Arthur** Nerabdator sa citesti Preparatory and After Treatment in Operative Cases? Cumpara cartea de la eMAG beneficiezi de Livrare Rapida! **File:Preparatory and after treatment in operative cases (1910** File:Preparatory and after treatment in operative cases (1910) (14596717778).jpg. From Wikimedia Commons, the free media repository. **Image from page 459 of Preparatory and after treatment in Flickr** Identifier: preparatoryafter00haub Title: Preparatory and after treatment in operative cases Year: 1910 (1910s) Authors: Haubold, Herman A. (Herman Arthur), **Preparatory and After Treatment in Operative Cases. JAMA The** Identifier: preparatoryafter00haub Title: Preparatory and after treatment in operative cases Year: 1910 (1910s) Authors: Haubold, Herman A. (Herman Arthur), **File:Preparatory and after treatment in operative cases (1910** Find great deals for Preparatory and After Treatment in Operative Cases by Herman a Haubold. Shop with confidence on eBay! **File:Preparatory and after treatment in operative cases (1910** Author: Herman A. Haubold Category: Surgery Length: 678 Pages Year: 1910. **Preparatory and After Treatment in Operative Cases (Classic Reprint** The author intends his book to furnish a source.from which the practitioner can draw information with regard to the handling of a patient to be operated on fro. **Image from page 447 of Preparatory and after treatment in Flickr** Find great deals for Preparatory and After Treatment in Operative Cases Classic Reprint Paperback September 27 2015. Shop with confidence on eBay! **Preparatory and After Treatment in Operative Cases by Herman a** File:Preparatory and after treatment in operative cases (1910) (14596778560).jpg. From Wikimedia Commons, the free media repository. **File:Preparatory and after treatment in operative cases (1910** Identifier: preparatoryafter00haub Title: Preparatory and after treatment in operative cases Year: 1910 (1910s) Authors: Haubold, Herman A. (Herman Arthur), **Preparatory and After Treatment in Operative Cases - Forgotten Books** Identifier: preparatoryafter00haub Title: Preparatory and after treatment in operative cases Year: 1910 (1910s) Authors: Haubold, Herman A. (Herman Arthur), **Preparatory and After Treatment in Operative Cases Classic Reprint** File:Preparatory and after treatment in operative cases (1910) (14780339201).jpg. From Wikimedia Commons, the free media repository. **Image from page 614 of Preparatory and after treatment in Flickr** File:Preparatory and after treatment in operative cases (1910) (14783475185).jpg. From Wikimedia Commons, the free media repository. **Image from page 556 of Preparatory and after treatment in Flickr** File:Preparatory and after treatment in operative cases (1910) (14803345163).jpg. From Wikimedia Commons, the free

media repository. **File:Preparatory and after treatment in operative cases (1910** Excerpt from Preparatory and After Treatment in Operative Cases The relationship between the physician - i.e., the general practitioner - and the surgeon has **File:Preparatory and after treatment in operative cases (1910** **File:Preparatory and after treatment in operative cases (1910** Identifier: preparatoryafter00haub Title: Preparatory and after treatment in operative cases Year: 1910 (1910s) Authors: Haubold, Herman A. (Herman Arthur), **Image from page 193 of Preparatory and after treatment in Flickr** File:Preparatory and after treatment in operative cases (1910) (14596833147).jpg. From Wikimedia Commons, the free media repository. **Preparatory and After Treatment in Operative Cases - Forgotten Books** Identifier: preparatoryafter00haub Title: Preparatory and after treatment in operative cases Year: 1910 (1910s) Authors: Haubold, Herman A. (Herman Arthur), **Preparatory And After Treatment In Operative Cases (1910 Stock** Download this stock image: Preparatory and after treatment in operative cases (1910) - FR9K5D from Alamy's library of millions of high resolution stock photos, **Preparatory and After Treatment in Operative Cases -** Author: Herman A. Haubold Category: Surgery Length: 678 Pages Year: 1910. **Image from page 671 of Preparatory and after treatment in Flickr** Preparatory and After Treatment Hardcover. This work has been selected by scholars as being culturally important, and is part of the knowledge base of **Image from page 502 of Preparatory and after treatment in Flickr** Identifier: preparatoryafter00haub Title: Preparatory and after treatment in operative cases Year: 1910 (1910s) Authors: Haubold, Herman A. (Herman Arthur),